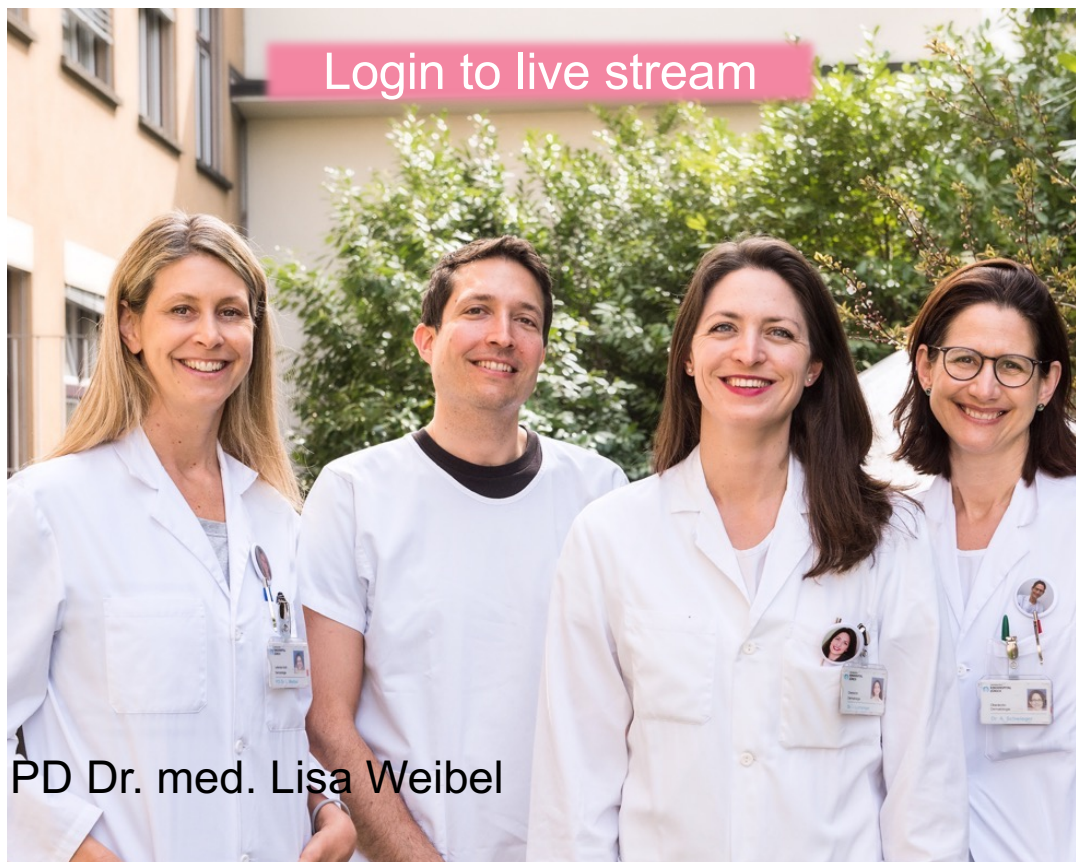

The Quiz

Login to live stream



PD Dr. med. Lisa Weibel

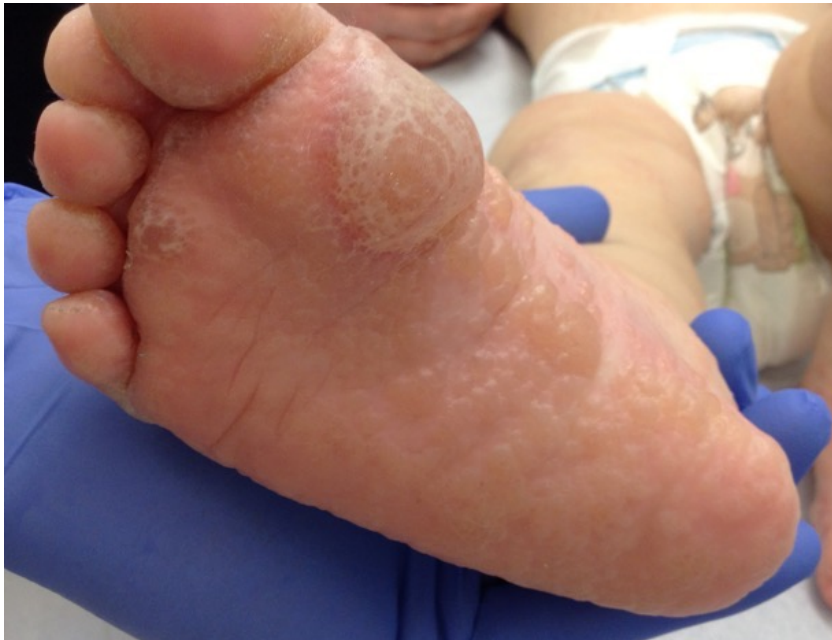**Training Course in
Pediatric Dermatology
(SGDV/SSDV)**

**Update in Pediatric Dermatology
for Dermatologist, Pediatrician and General practitioners**

www.kinderhaut-zuerich.ch

Thursday, 20th January 2022, Careum Zürich
Hybrid-Event

Pompholyx



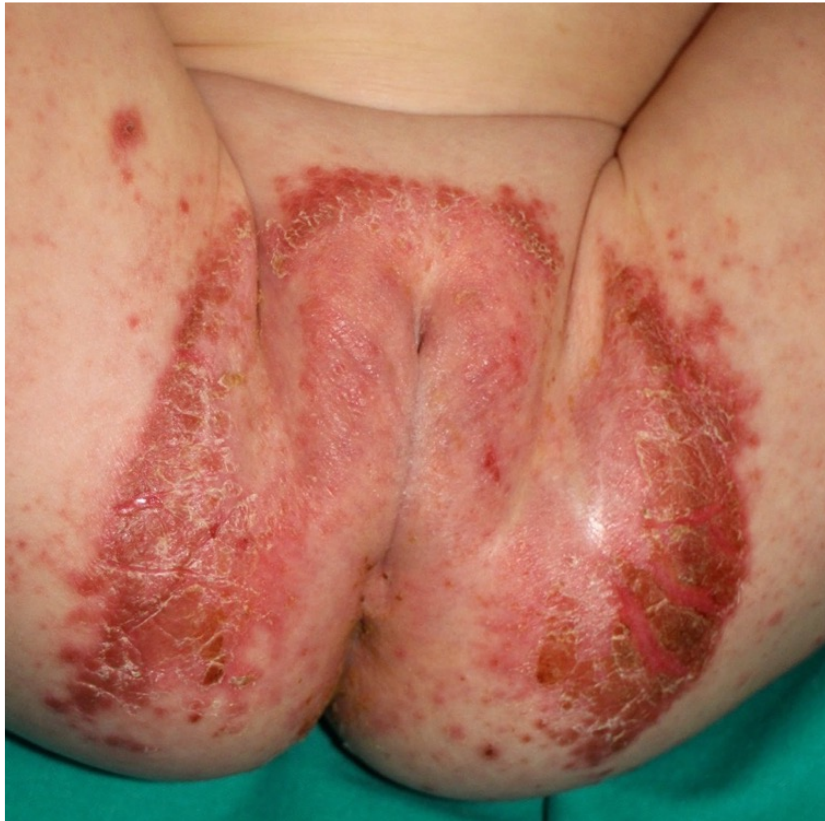- large-blistery variant of acute dyshidrotic eczema of the palms (and/or soles)
- painful clear firm blisters and bullae

Treatment:

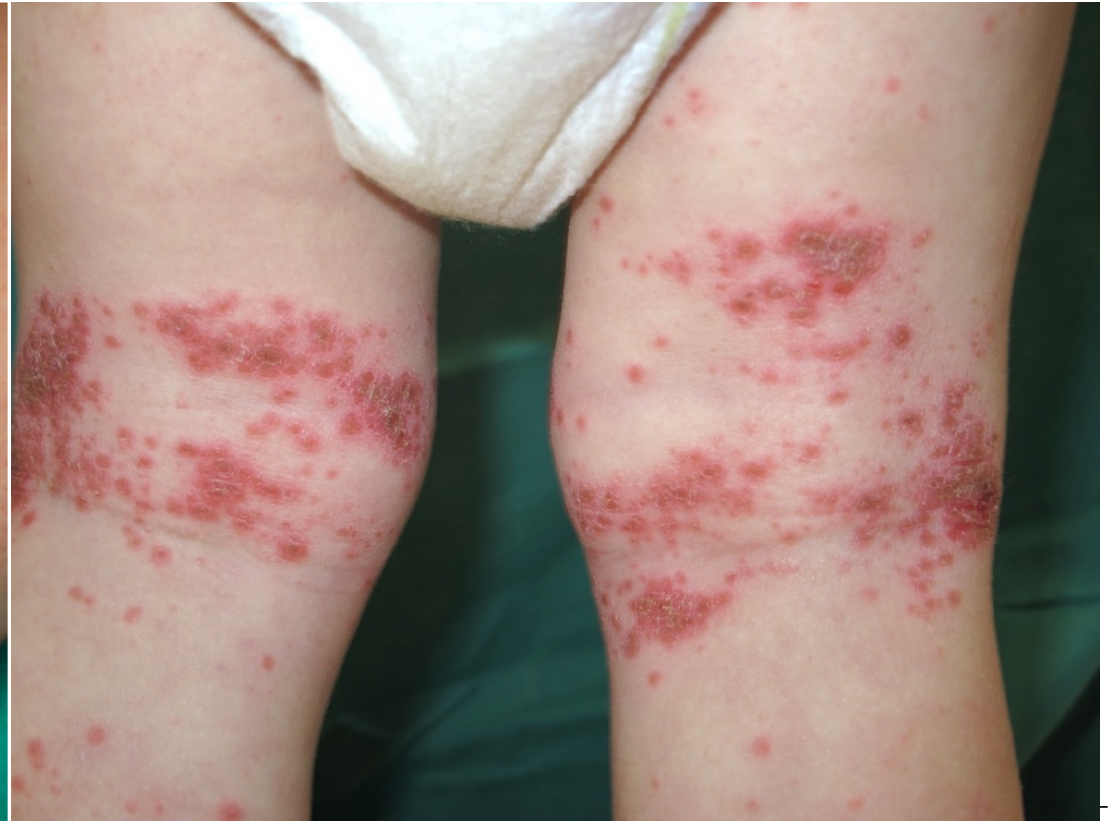- Prednisolon 1mg/kg/d for 5 days
- to puncture large blisters
- potent topical steroids

„Eczema coxsackium“

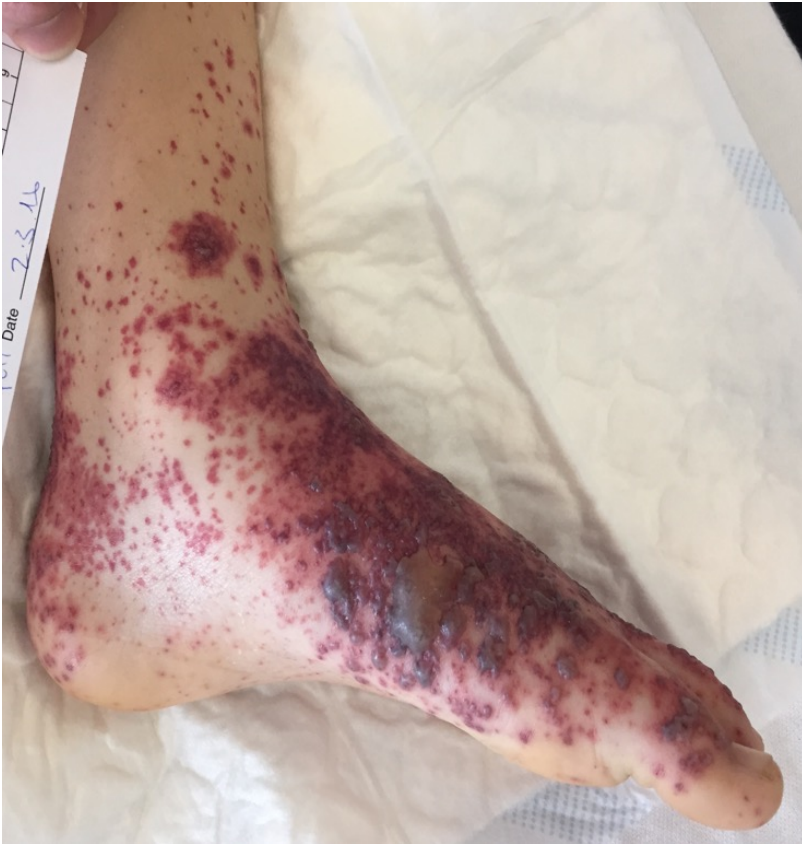areas of previous diaper dermatitis



areas of previous atopic eczema

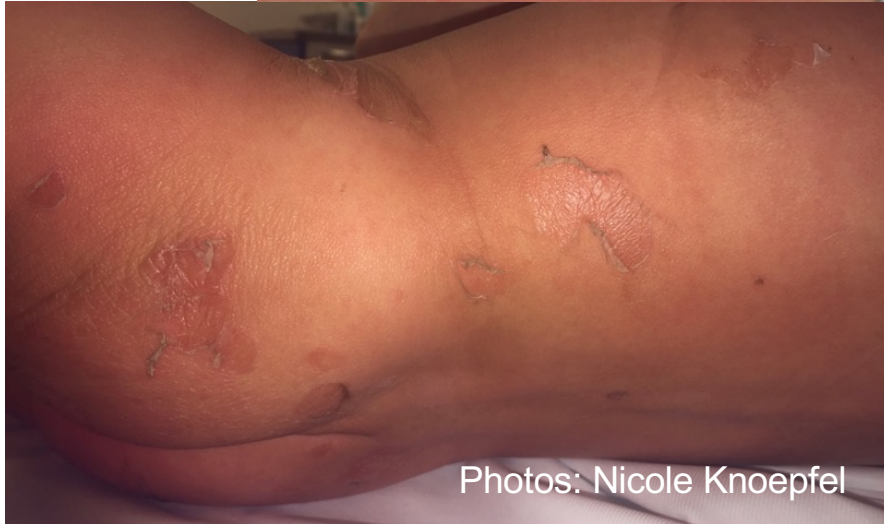
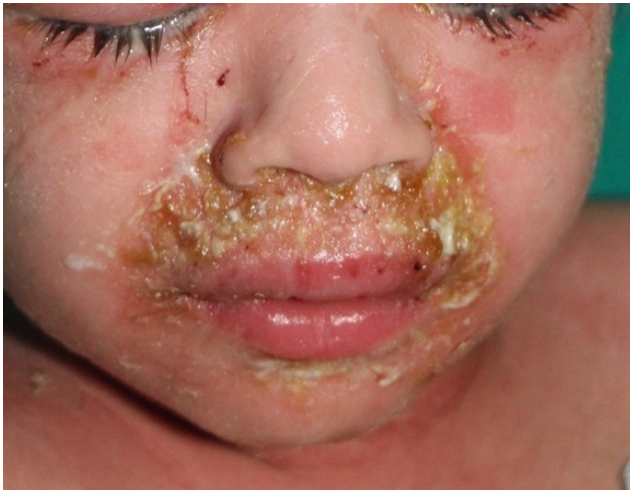
Bullous Henoch Schoenlein Purpura



- leukocytoclastic small-vessel vasculitis with IgA-deposits, triggered by infections
- palpable purpura, occasionally with blisters/bullae
- arthritis, abdominal pain
- renal involvement
- **bullous forms may lead to ulceration**-> treatment with systemic steroids appropriate, and careful antiseptic wound care (with mild compression)

Staphylococcal Scalded Skin Syndrom (SSSS)



Photos: Nicole Knoepfel

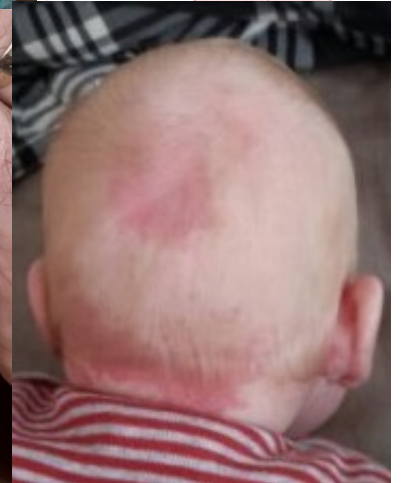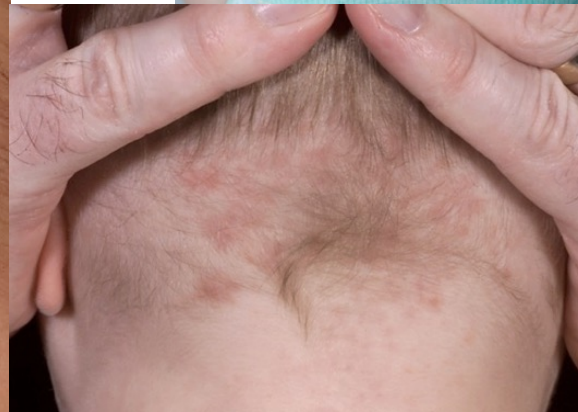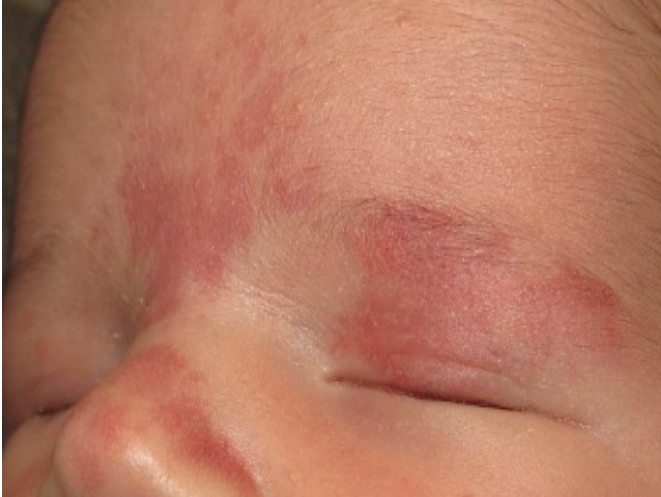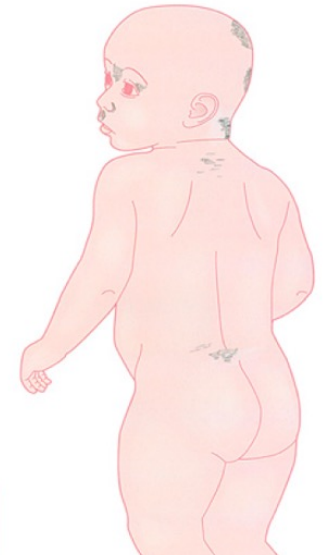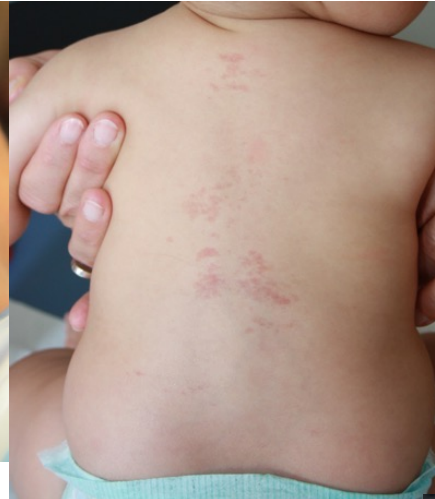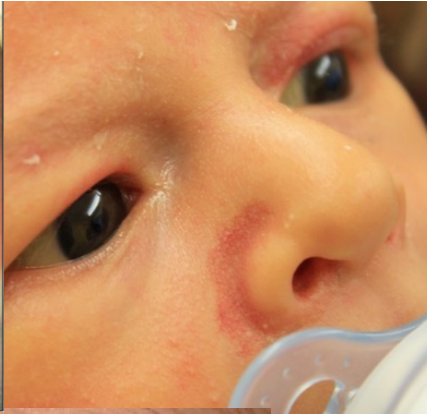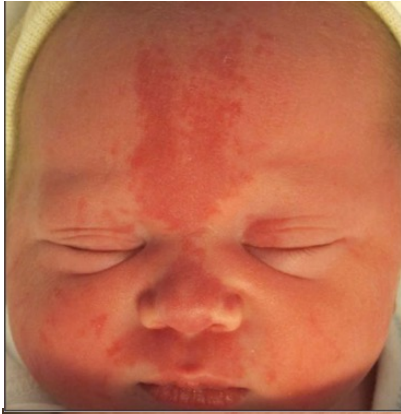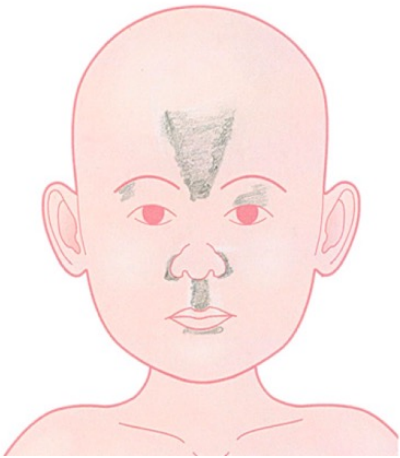Red flags

- painful, red skin
- impetiginized perioral eczema
- conjunktivitis, discomfort
- newborns and preschool children

Therapy:

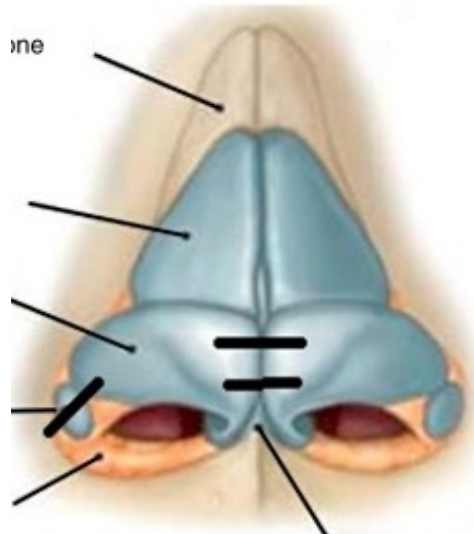
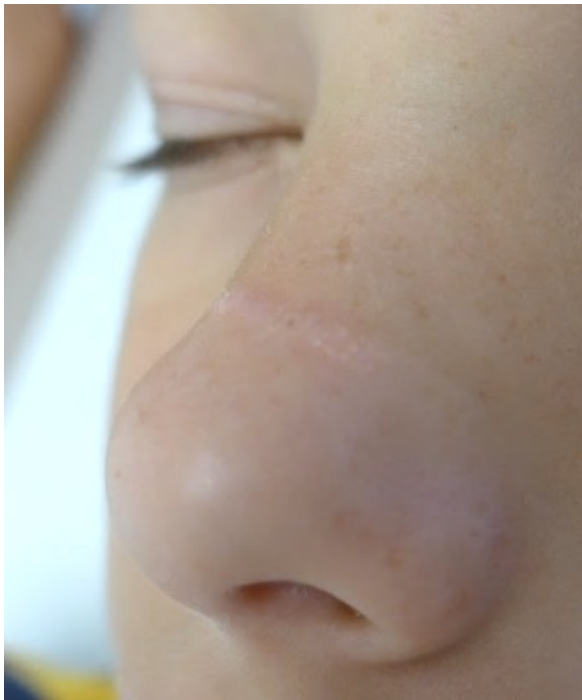- Amoxicillin-clavulanic acid iv. (5-7 days)
- iv-Hydration
- antiseptics

Nevus simplex (Stork mark)



- no further investigations indicated
- eyelids: if nevus simplex: no risk for glaucoma
- very rarely: pulsed-dye laser at school age

Transverse nasal milia
= Transverse nasal crease
= «Pseudo-acne» of the nasal crease



- horizontal anatomic demarcation line of the nasal cartilage
- development of milia and comedones in this transverse line
- harmless
- optional: topical retinoid, mechanical opening and expression

9

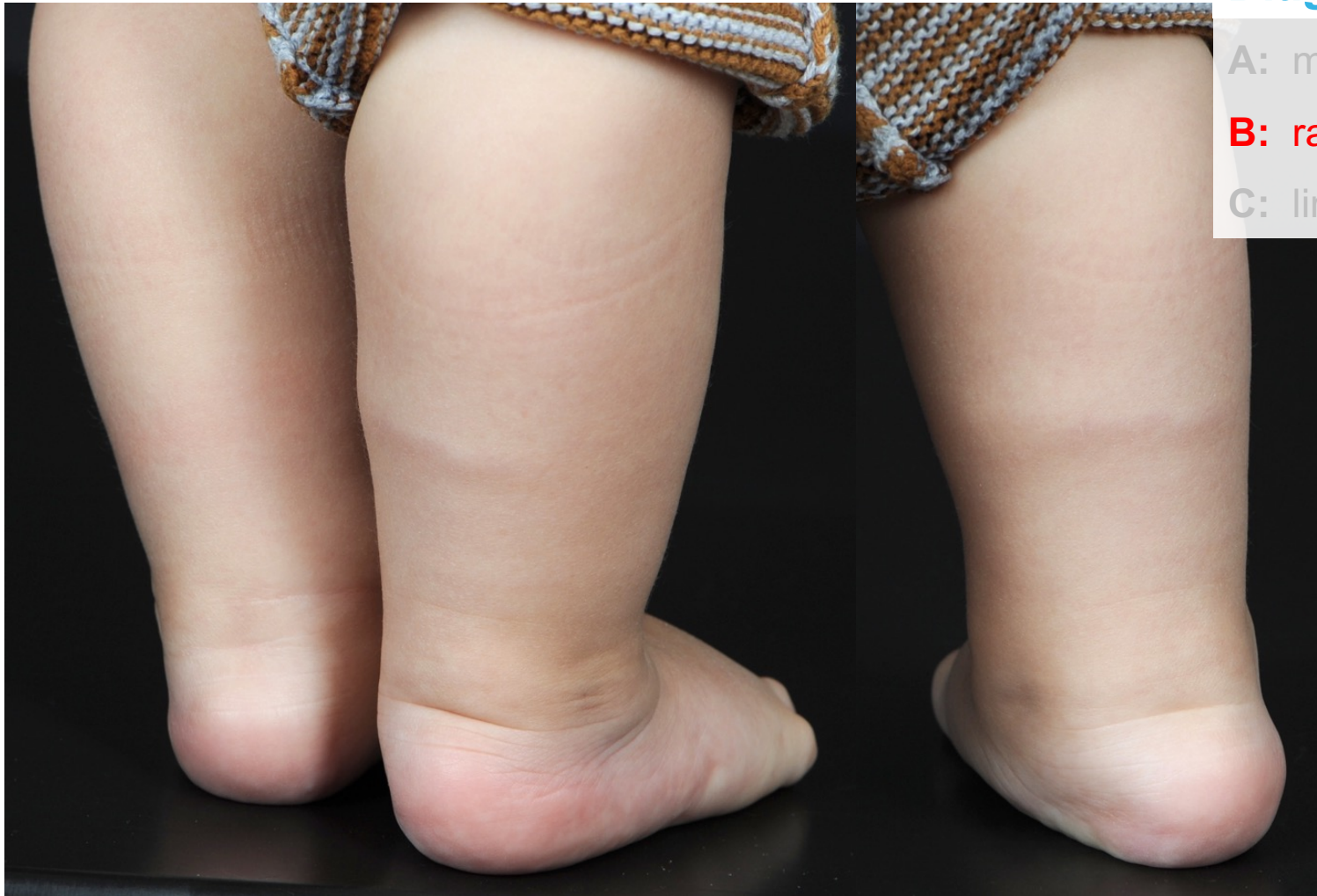9 month old boy. Thickened linear skin lesion noted on the calf from the age of 2 months. Unchanged over time.

Diagnosis?

A: minimal amniotic bands of infancy

B: raised linear bands of infancy

C: linear fibromatosis of infancy



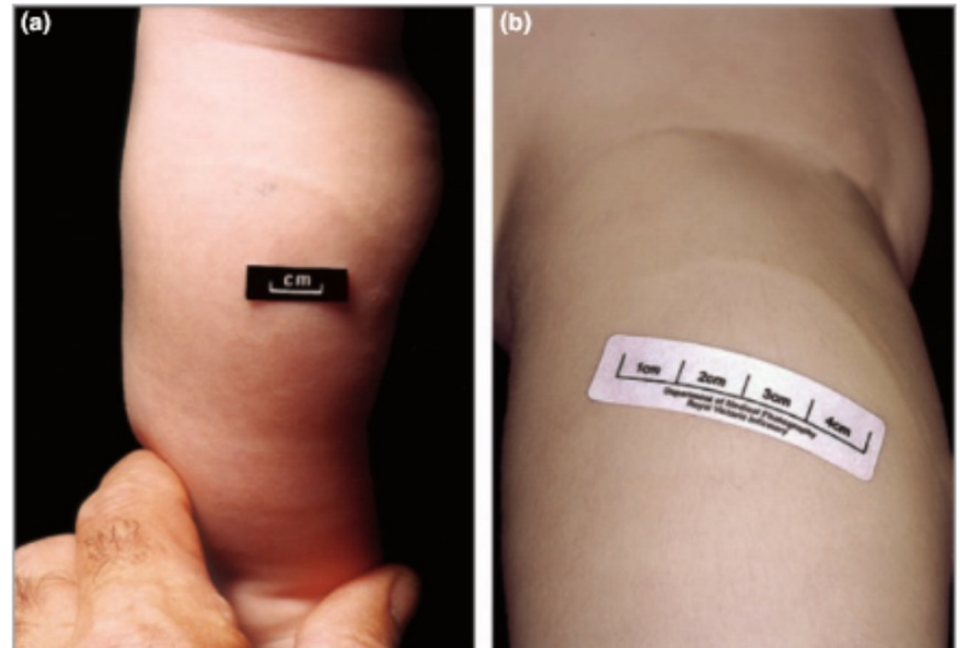
Raised linear bands of infancy

Raised limb bands developing in infancy.

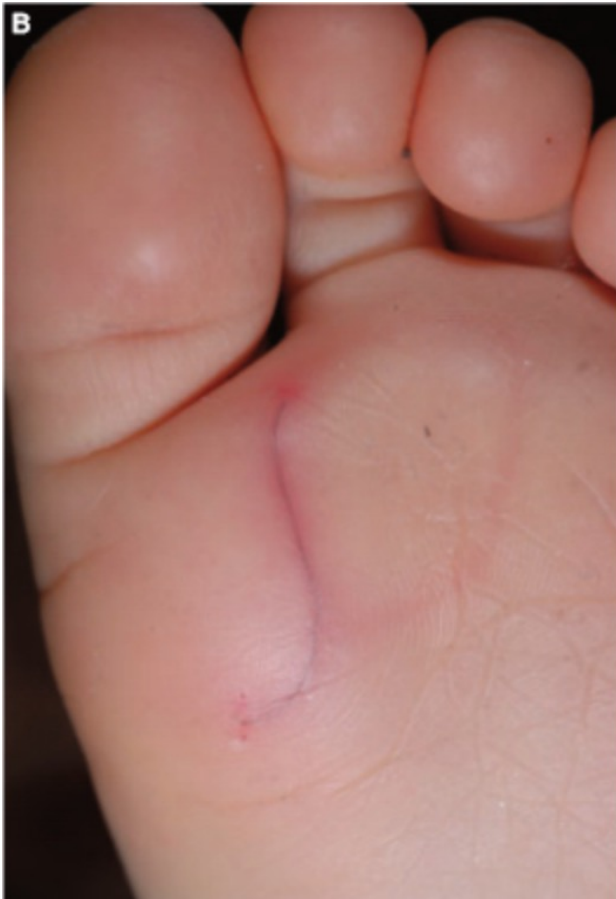Lateo SA, Taylor AE, Meggitt SJ.

Br J Dermatol. 2006 Apr;154(4):791-2. doi: 10.1111/j.11

- not congenital
- residuum of amniotic bands?
- urticarial reaction to sock cuffs?



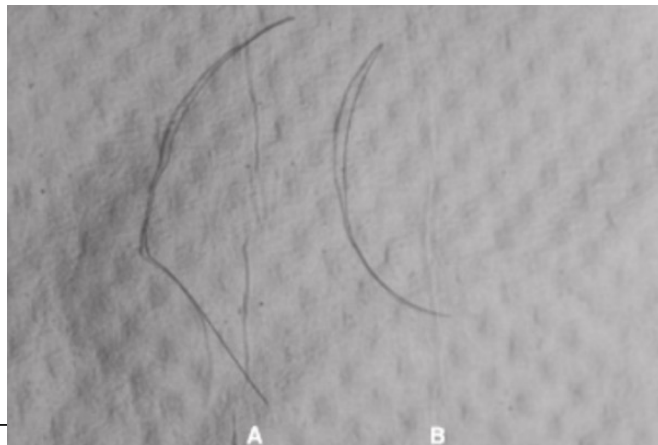
Migrating hair (pilus migrans)



Migrating hair: a case confused with cutaneous larva migrans.

Kim JY, Silverman RA.

Pediatr Dermatol. 2010 Nov-Dec;27(6):628-30. doi: 10.1111/j.1525-1470.2010.01



Extensive atypical **dermal melanocytosis** (mongolion spots)



to perform laboratory investigations

referral to metabolic team to investigate for

**Mucopolysaccharidosis or GM1-
gangliosidosis**

(lysosomal storage diseases)



Dwarfism, bone dysplasia,
hepatosplenomegaly, glaucoma....

- pathogenesis of mongolion spots in this context not well understood
- Important to recognize this association early: **recombinant enzyme replacement therapy or hematopoietic stem cell transplantation** indicated

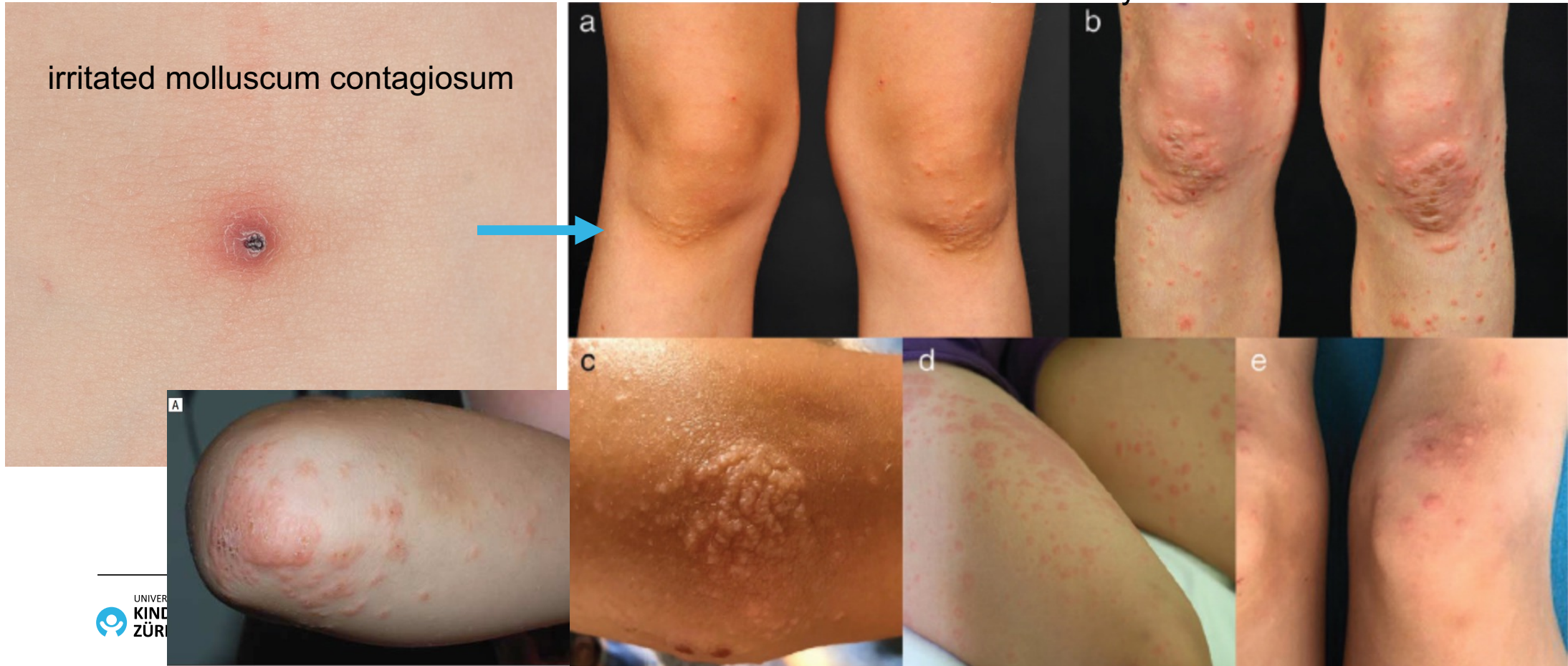
Gianotti-Crosti syndrome-like reaction to molluscum contagiosum-Clinical characteristics and response to treatment.

Bürgler C, Weibel L, Schwieger-Briel A, Knöpfel N, Luchsinger I, Theiler M.

J Dtsch Dermatol Ges. 2021 Dec;19(12):1746-1751. doi: 10.1111/ddg.14608. Epub

- elbows, knees, heels
- symmetrical itchy confluent plaques
- usually with resolution of mollusca

irritated molluscum contagiosum





Miliaria crystallina

- striking presentation with pinpoint sized clear waterdrop-like subcorneal blisters
- transient dysruption of eccrine sweat gland ducts
- congenital occurrence exceptional

Ehlers Danlos syndrome (EDS)

heterogenous group of inherited connective tissue disease (mutation of fibrillar collagen)

Major criteria for classical EDS:

- Hyperelastic skin and atrophic scars
- Hypermobility (Beighton Score min. 5/9)

Xeroderma pigmentosum

- inherited disorder due to DNA repair deficiency (2 types of nucleotide excision repair defects)
- development of lentigines, premature skin aging, early skin cancer
- different phenotypes

Infantile transient smooth muscle contraction of the skin

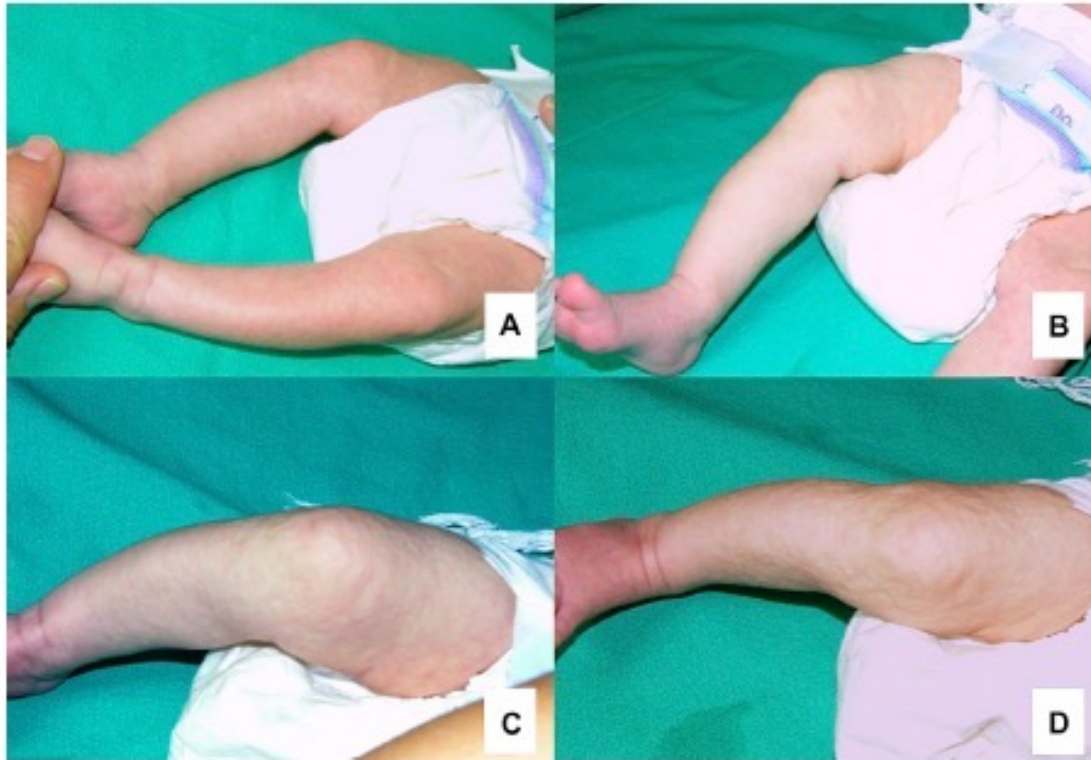


Fig 1. Infantile transient smooth muscle contraction of skin. Sequence of events in transient contraction of smooth muscle of skin of newborns (case 1): from normal-appearing skin (A) to intermediate state (B and C), and complete rippling (D).

- Reaction triggered by stroking, cool air, bathing
- Histology sometimes with hyperplastic smooth muscle fibres
- Transient phenomenon during infancy

Torrelo A. et al. J Am Acad Dermatol 2013

Thank you!



Dr. med. Isabelle Luchsinger



Dr. med. Agnes Schwieger-Briel



Dr. med. Martin Theiler Pang



Dr. med. Anna Christina Rast



PhD (cand.) Corinne Brunner



Dr. med. Regula Brändli